

# Klinische und radiologische Vollremission nach neoadjuvanter RTX – was tun?

K.S. Glaser, R.H. Fortelny, M. Brunialti,  
R.Roehle, A.H.Petter-Puchner

Abteilung für Allgemein-, Viszeral- und  
Tumorchirurgie



ISDS International Society for Digestive Surgery



# Surgery vs. Watchful waiting in low rectal carcinoma

„This is too academic and does not affect my work, we strictly adhere to guidelines...“

In contrast to negative restaging (no malignoma in colonoscopy, EUS, MRI, CT) and no vital tumor in resectional specimen.

# Methods

- 9 patients (6 female, 3 male; median 78 years; 53-83a)
- Low rectal carcinoma (< 6cm ab ano)
- Unintentional proceeding-**APE rather than TME pending....**
- Staging: T2 N1-T3 N0, N1
- Complete remission 12 weeks after longterm RCT
- Restaging: MRI,CT, Palpation, Endosono, Rektoskopy
- All patients multimorbid and/or opposing stoma
- Observation period in 6 patients without clinical and radiological signs of recurrence: 9,5,3,2,2,1.5 yrs post RCT

# Proponents of two very different treatment strategies for low rectal carcinoma



... recently more intimate (opinion !!)

# Surgery (alone)/ Watchful waiting

Good arguments for both intentional strategies

Avoiding significant side effects of RCT

Avoiding significant side effects of surgery  
(including burden of outcome-APE)

# Polarity in treatment of **distal RC**

**“Wait and see approach”** in patients after neoadjuvant radio-chemotherapy for distal rectal cancer

*The use of strict selection criteria of patients after neoadjuvant CRT has resulted **in excellent long-term results with no oncological compromise** after observation alone in patients **with complete clinical response. Recurrences are detectable** by clinical assessment and frequently amenable to salvage procedures.*

**Habr-Gama, Surg Oncol Clin N Am 2010**

# Preoperative High-resolution Magnetic Resonance Imaging Can Identify Good Prognosis Stage I, II, and III Rectal Cancer Best Managed by Surgery Alone: A Prospective, Multicenter, European Study That Recruited Consecutive Patients With Rectal Cancer

- RESULTS: Of 374 patients followed up in the MERCURY study, 122 (33%) were defined as "good prognosis" stage III or less on MRI. Overall and disease-free survival for all patients with MRI "good prognosis" stage I, II and III disease at 5 years was 68% and 85%, respectively. **The local recurrence rate for this series of patients predicted to have a good prognosis tumor on MRI was 3%.**
- CONCLUSIONS: The preoperative identification of good prognosis tumors using MRI will allow stratification of patients and better targeting of preoperative therapy. This study confirms the ability of MRI to select patients who are likely to have a good outcome with primary surgery alone.

Taylor, Mercury Group, Ann Surg 2011

# Sequel study AnnSurg 2016

*Ann Surg.* 2016 Apr;263(4):751-80. doi: 10.1097/SLA.0000000000001193.

## **Prospective Validation of a Low Rectal Cancer Magnetic Resonance Imaging Staging System and Development of a Local Recurrence Risk Stratification Model: The MERCURY II Study.**

Battersby NJ<sup>1</sup>, How P, Moran B, Stelzner S, West NP, Branaqan G, Strassburg J, Quirke P, Tekkis P, Pedersen BG, Gudgeon M, Heald B, Brown G; MERCURY II Study Group.

### ⊕ Author information

#### Abstract

**OBJECTIVE:** This study aimed to validate a magnetic resonance imaging (MRI) staging classification that preoperatively assessed the relationship between tumor and the low rectal cancer surgical resection plane (mrLRP).

**BACKGROUND:** Low rectal cancer oncological outcomes remain a global challenge, evidenced by high pathological circumferential resection margin (pCRM) rates and unacceptable variations in permanent colostomies.

**METHODS:** Between 2008 and 2012, a prospective, observational, multicenter study (MERCURY II) recruited 279 patients with adenocarcinoma 6 cm or less from the anal verge. MRI assessed the following: mrLRP "safe or unsafe," venous invasion (mrEMVI), depth of spread, node status, tumor height, and tumor quadrant. MRI-based treatment recommendations were compared against final management and pCRM outcomes.

**RESULTS:** Overall pCRM involvement was 9.0% [95% confidence interval (CI), 5.9-12.3], significantly lower than previously reported rates of 30%. Patients with no adverse MRI features and a "safe" mrLRP underwent sphincter-preserving surgery without preoperative radiotherapy, resulting in a 1.6% pCRM rate. The pCRM rate increased 5-fold for an "unsafe" compared with "safe" preoperative mrLRP [odds ratio (OR) = 5.5; 95% CI, 2.3-13.3]. Posttreatment MRI reassessment indicated a "safe" ymrLRP in 33 of 113 (29.2%), none of whom had ypCRM involvement. In contrast, persistent "unsafe" ymrLRP posttherapy resulted in 17.5% ypCRM involvement. Further independent MRI assessed risk factors were EMVI (OR = 3.8; 95% CI, 1.5-9.6), tumors less than 4.0 cm from the anal verge (OR = 3.4; 95% CI, 1.3-8.8), and anterior tumors (OR = 2.8; 95% CI, 1.1-6.8).

**CONCLUSIONS:** The study validated MRI low rectal plane assessment, reducing pCRM involvement and avoiding overtreatment through selective preoperative therapy and rationalized use of permanent colostomy. It also highlights the importance of posttreatment restaging.



[Eur J Surg Oncol](#). 2014 Feb;40(2):227-33. doi: 10.1016/j.ejso.2013.11.029. Epub 2013 Dec 14.

## Impaired continence function five years after intensified chemoradiation in patients with locally advanced rectal cancer.

[Horisberger K](#)<sup>1</sup>, [Rothenhoefer S](#)<sup>2</sup>, [Kripp M](#)<sup>3</sup>, [Hofheinz RD](#)<sup>3</sup>, [Post S](#)<sup>4</sup>, [Kienle P](#)<sup>4</sup>.

### **+** Author information

#### **Abstract**

**AIMS:** While the influence on survival is only seen in patients with complete regression after neoadjuvant treatment in locally advanced rectal cancer the impairment of the continence capacity weighs even more for patients with little oncological benefit.

**METHODS:** Patients treated with intensified preoperative radiochemotherapy patients treated only by TME surgery were asked five years after treatment to complete the Wexner and SF-12 quality of life questionnaire.

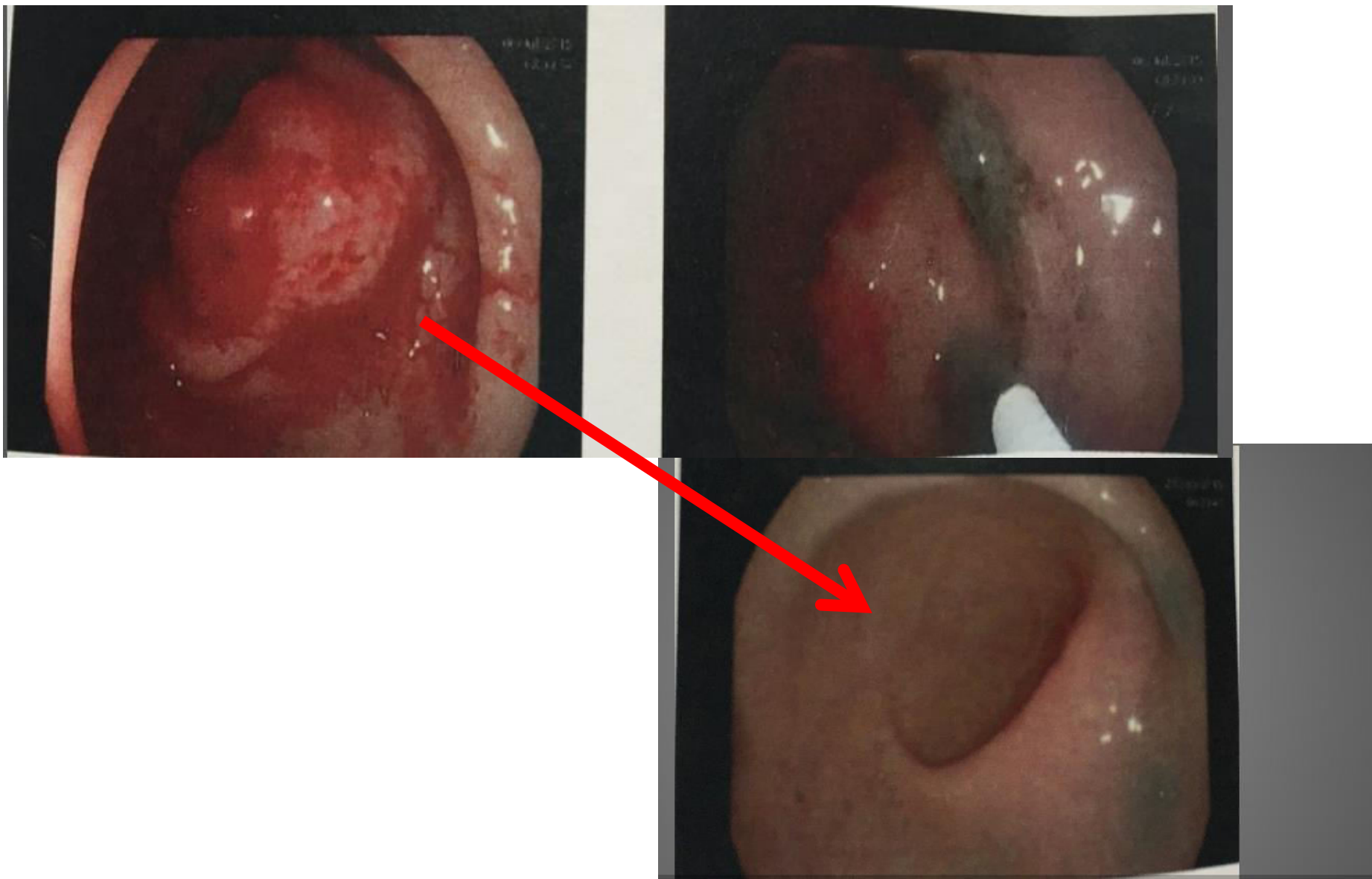
**RESULTS:** 25 after neoadjuvant treatment had a median Wexner score of 14 [3-20] after 63 [42-78] months. Histopathological stage or grade of regression did not influence the Wexner score ( $p = 0.76$ , resp.  $p = 0.9$ ). 12% describe themselves as being permanently continent; 40% are stool incontinent "always" or "most of the time". 68% are always wearing pads. 29 patients after TME only showed a median Wexner score of 5 [range 0-17] after 66 months [26-133]. SF-12 showed significantly lower values in physical ( $p = 0.02$ ) as well as mental summary scales ( $p = 0.015$ ) in patients after RCTX while patients after radical surgery showed no difference to the norm population.

**CONCLUSION:** This study shows that continence is significantly worse five years after neoadjuvant treatment. Moreover, patients after neoadjuvant treatment and surgery have impaired quality of life compared to norm population. These results may contribute to the discussion of only applying neoadjuvant chemoradiation selectively in patients with advanced rectal cancer.

# What did we do?

- Patients gave informed written consent for watchful waiting as all of them rejected to a stoma or were seriously ill (ASA 3-4)
- At six weeks significant remission – complete remission after 12 weeks
- All 9 patients were closely followed including MRI, EUS, Rectoscopy and palpation
- Short intervals for follow up during the first year
- 2 remained free of disease more than 5 years post RCT, 4 under observation 1.5 to 3 years after RCT
- 3 patients underwent TEM with one local recurrence

39 male patient, full remission **within 3 months**



# Recent reviews on watchful waiting strategy

[Curr Treat Options Oncol](#). 2016 May;17(5):22. doi: 10.1007/s11864-016-0398-0.

## Watch and Wait: Is Surgery Always Necessary for Rectal Cancer?

Hawkins AT<sup>1</sup>, Hunt SR<sup>2</sup>.

### ⊕ Author information

#### Abstract

**OPINION STATEMENT:** Despite decades of high-quality research, the treatment of rectal cancer remains a work in progress. The interplay between chemotherapy, radiotherapy, and surgery is under constant rearrangement and refinement. Through this all, the desire to preserve the anal sphincters and quality of life remains at the forefront. In the past decade, standard of care for stage II or III rectal cancers in the USA has been neoadjuvant chemoradiation therapy (CRT) followed by radical surgical resection of the rectum. While timing and sequence of the CRT continues to evolve, surgical resection has remained essential in treatment. This stands in contrast to anal cancer, where surgery is reserved purely for salvage. This article describes a treatment strategy that attempts to treat rectal adenocarcinoma with CRT alone, reserving surgery for failure or salvage. Of the studies performed to date, a number are methodologically sound and show promise. However, the body of evidence has yet to reach a size to sway practitioners from the established trinity of chemotherapy, radiotherapy, and surgery. Interestingly, few trials administer post treatment full-dose systemic chemotherapy, which is the standard of care in patients undergoing surgical resection. Better identification of patients that will have complete cure from this approach, combined with long-term outcome data on salvage patients, is necessary for this therapy to be universally embraced.

## Nonoperative management of rectal cancer.

Torok JA<sup>1</sup>, Palta M<sup>1</sup>, Willett CG<sup>1</sup>, Czito BG<sup>1</sup>.

### ⊕ Author information

#### Abstract

Surgery has long been the primary curative modality for localized rectal cancer. Neoadjuvant chemoradiation has significantly improved local control rates and, in a significant minority, eradicated all disease. Patients who achieve a pathologic complete response to neoadjuvant therapy have an excellent prognosis, although the combination treatment is associated with long-term morbidity. Because of this, a nonoperative management (NOM) strategy has been pursued to preserve sphincter function in select patients. Clinical and radiographic findings are used to identify patients achieving a clinical complete response to chemoradiation, and they are then followed with intensive surveillance. Incomplete, nonresponding and those demonstrating local progression are referred for salvage with standard surgery. Habr-Gama and colleagues have published extensively on this treatment strategy and have laid the groundwork for this approach.

This watch-and-wait strategy has evolved over time, and several groups have now reported their results, including recent prospective experiences. Although initial results appear promising, several significant challenges remain for NOM of rectal cancer. Further study is warranted before routine implementation in the clinic.

# TEM obviously frequent in RCT responders in watchful waiting regimen

Minim Invasive Ther Allied Technol. 2014 Mar;23(2):63-9. doi: 10.3109/13645706.2014.893891.

## **Pitfalls of transanal endoscopic microsurgery for rectal cancer following neoadjuvant chemoradiation therapy.**

Habr-Gama A<sup>1</sup>, São Julião GP, Perez RO.

### **⊕ Author information**

#### **Abstract**

Transanal endoscopic microsurgery has become a very useful surgical tool for the management of selected cases of rectal cancer. However, the considerably high local recurrence rates led to the introduction of neoadjuvant therapies including radiation with or without chemotherapy. This treatment strategy may result in significant rates of tumor regression allowing the procedure to be offered to a significant proportion of cases. On the other hand, neoadjuvant chemoradiation (CRT) may also determine wound-healing difficulties with significant postoperative pain. In addition, salvage total mesorectal excision in the case of local recurrence may also be a challenging task. Finally, accurate selection criteria for this minimally invasive approach are still lacking and may be influenced by baseline staging, post-treatment staging and final pathology information. Ultimately, selection of patients for this treatment modality remains a significant challenge for the colorectal surgeon who should be aware of the pitfalls of this procedure in the setting of neoadjuvant CRT.

## Transanal endoscopic microsurgery for residual rectal cancer (ypT0-2) following neoadjuvant chemoradiation therapy: another word of caution.

Perez RO<sup>1</sup>, Habr-Gama A, Lynn PB, São Julião GP, Bianchi R, Proscurshim I, Gama-Rodrigues J.

### ⊕ Author information

#### Abstract

**BACKGROUND:** Significant tumor downstaging among patients with rectal cancer following neoadjuvant chemoradiation has raised the issue of offering patients with small residual cancers restricted to the bowel wall an alternative treatment strategy to total mesorectal excision. Transanal endoscopic microsurgery may allow proper primary tumor resection with promising oncological outcomes, less postoperative morbidity, and minimal long-term sexual, urinary, and fecal continence disorders in comparison with radical resection.

**OBJECTIVE:** The aim of this study was to determine the oncological outcomes of patients with residual rectal cancers restricted to the rectal wall (ypT0-2) following neoadjuvant chemoradiation and transanal endoscopic microsurgery.

**DESIGN:** This study considered a prospective cohort of patients with residual rectal cancers following neoadjuvant chemoradiation treated by transanal endoscopic microsurgery and no additional systemic therapy.

**SETTINGS:** This study was a single-institution experience.

**PATIENTS:** Patients with adenocarcinoma of the rectum located no more than 7 cm from the anal verge and endorectal ultrasound- or magnetic resonance-staged cT2-4N0-2M0 treated by neoadjuvant chemoradiation (50.4-54 Gy and 5-fluorouracil-based chemotherapy) were eligible for the study. Patients with small residual tumors ( $\leq 3$  cm) radiologically staged ycT0-2N0 were treated by transanal endoscopic microsurgery.

**INTERVENTIONS:** Transanal endoscopic microsurgery was performed.

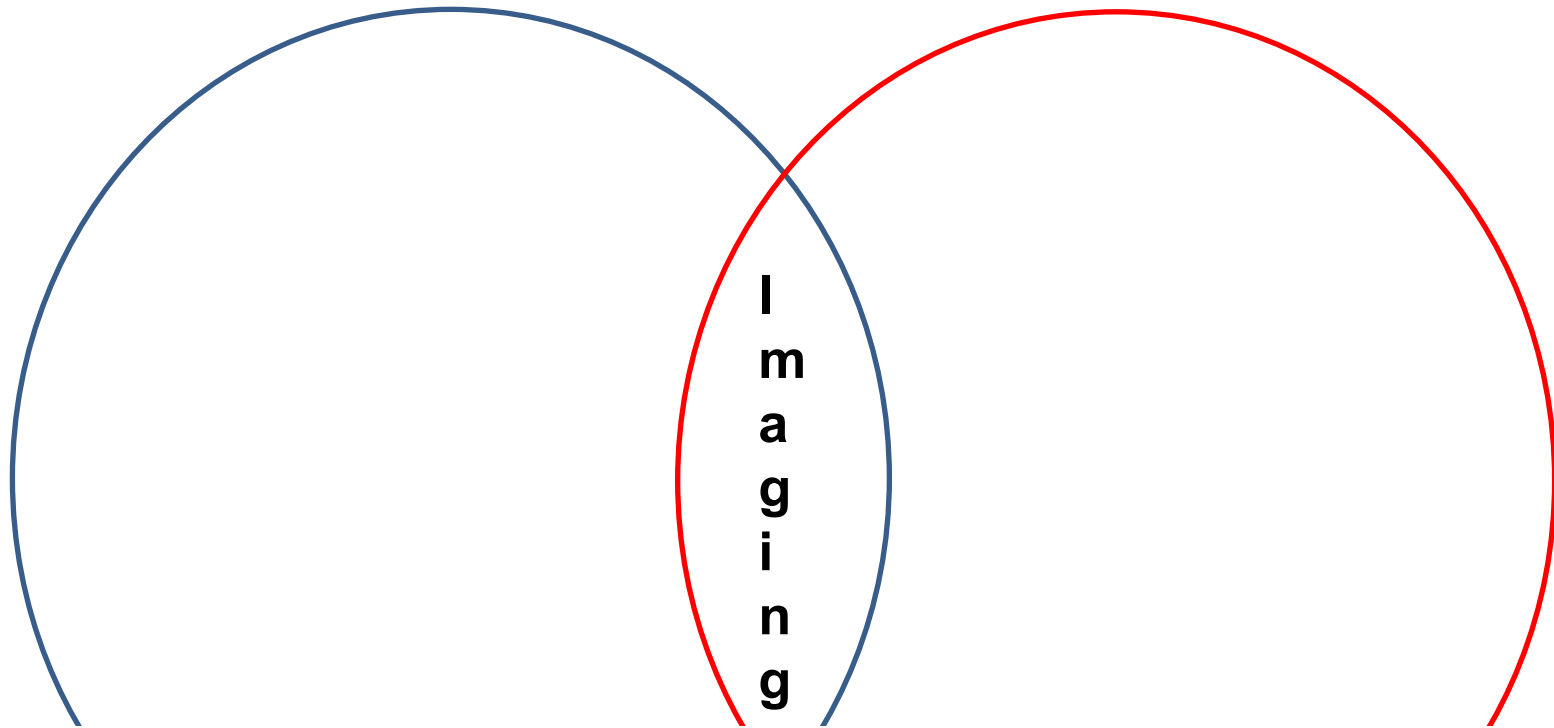
**MAIN OUTCOME MEASURES:** The primary outcome measured was local recurrence.

**RESULTS:** Of the 27 patients treated by transanal endoscopic microsurgery, 3 had ypT0, 6 had ypT1, and 18 had ypT2 cancers. All patients underwent R0 transanal endoscopic microsurgery excision. Local recurrence was observed in 4 (15%) patients after a median follow-up of 15 months. Only lymphovascular invasion was an independent predictive factor for local failure ( $p = 0.04$ ). Tumor size, ypT status, T-status downstaging, lateral/radial margins, and tumor regression grade were not predictors of local failure.

**LIMITATIONS:** This study was limited by the small sample size and limited follow-up.

**CONCLUSIONS:** A local failure rate of 15% after transanal endoscopic microsurgery for patients with residual rectal cancers restricted to the bowel wall (ypT0-2) may limit the indication of this procedure to highly selected patients as an alternative to standard radical total mesorectal excision.

# Surgery (alone) / Watchful waiting



[Colorectal Dis.](#), 2014 May;16(5):334-7. doi: 10.1111/codi.12627.

**Report from a consensus meeting: response to chemoradiotherapy in rectal cancer - predictor of cure and a crucial new choice for the patient: on behalf of the Champalimaud 2014 Faculty for 'Rectal cancer: when NOT to operate'.**

[Heald RJ](#)<sup>1</sup>, [Beets G](#), [Carvalho C](#).

**Tumor biology, Epigenetics, Environmental factors all unknown.....**



# Crucial role of imaging

- T1, T2 EUS
- T2, T3 (upper 1/3, colonic) maybe CT
- Low RC, L, N only MRI (preferably diffusion weighted)
- Diffusion weighted T2-MRI for assessment of local response after neoadjuvant therapy
- (Multi Slice Hydro CT for staging of RC)

[Eur J Surg Oncol](#). 2014 Apr;40(4):469-75. doi: 10.1016/j.ejso.2013.10.029. Epub 2013 Dec 14.

**EURECCA consensus conference highlights about colon & rectal cancer multidisciplinary management: the radiology experts review.**

[Tudyka V](#)<sup>1</sup>, [Blomqvist L](#)<sup>2</sup>, [Beets-Tan RG](#)<sup>3</sup>, [Boelens PG](#)<sup>4</sup>, [Valentini V](#)<sup>5</sup>, [van de Velde CJ](#)<sup>6</sup>, [Diequez A](#)<sup>7</sup>, [Brown G](#)<sup>8</sup>.

*J Clin Oncol*. 2014 Jan 1;32(1):34-43. doi: 10.1200/JCO.2012.45.3258. Epub 2013 Nov 25.

## Preoperative magnetic resonance imaging assessment of circumferential resection margin predicts disease-free survival and local recurrence: 5-year follow-up results of the MERCURY study.

Taylor FG<sup>1</sup>, Quirke P, Heald RJ, Moran BJ, Blomqvist L, Swift IR, Sebag-Montefiore D, Tekkis P, Brown G; Magnetic Resonance Imaging in Rectal Cancer European Equivalence Study Study Group.

### + Collaborators (95)

### + Author information

#### Abstract

**PURPOSE:** The prognostic relevance of preoperative high-resolution magnetic resonance imaging (MRI) assessment of circumferential resection margin (CRM) involvement is unknown. This follow-up study of 374 patients with rectal cancer reports the relationship between preoperative MRI assessment of CRM staging, American Joint Committee on Cancer (AJCC) TNM stage, and clinical variables with overall survival (OS), disease-free survival (DFS), and time to local recurrence (LR).

**PATIENTS AND METHODS:** Patients underwent protocol high-resolution pelvic MRI. Tumor distance to the mesorectal fascia of  $\leq 1$  mm was recorded as an MRI-involved CRM. A Cox proportional hazards model was used in multivariate analysis to determine the relationship of MRI assessment of CRM to survivorship after adjusting for preoperative covariates.

**RESULTS:** Surviving patients were followed for a median of 62 months. The 5-year OS was 62.2% in patients with MRI-clear CRM compared with 42.2% in patients with MRI-involved CRM with a hazard ratio (HR) of 1.97 (95% CI, 1.27 to 3.04;  $P < .01$ ). The 5-year DFS was 67.2% (95% CI, 61.4% to 73%) for MRI-clear CRM compared with 47.3% (95% CI, 33.7% to 60.9%) for MRI-involved CRM with an HR of 1.65 (95% CI, 1.01 to 2.69;  $P < .05$ ). Local recurrence HR for MRI-involved CRM was 3.50 (95% CI, 1.53 to 8.00;  $P < .05$ ). MRI-involved CRM was the only preoperative staging parameter that remained significant for OS, DFS, and LR on multivariate analysis.

**CONCLUSION:** High-resolution MRI preoperative assessment of CRM status is superior to AJCC TNM-based criteria for assessing risk of LR, DFS, and OS. Furthermore, MRI CRM involvement is significantly associated with distant metastatic disease; therefore, colorectal cancer teams could intensify treatment and follow-up accordingly to improve survival outcomes.

# What can we learn-1?

- Full remission after RCT happens and can translate to a stable disease free state
- The first 2/3 Years are crucial for DFS
- Patients eligible for watchful waiting are probably the same as for surgery alone
- Unfortunately, selection is still difficult
- Imaging is a key element to predict and to identify the course of treatment (Diffusion weighted MRI)
- Avoiding neoadjuvant treatment misses cases of full remission
- Watchful waiting is an experimental approach, but feasible in comorbid and non-compliant patients or under study aspects

# What can we learn-2?

- In young, otherwise „healthy“ patients the same imaging and stratification modalities should be used to consider a surgery alone strategy or otherwise adhere to guidelines.
- The concern of RCT related side effects must worry everyone of us.

# Was tun?

- Nicht verboten
- Diskussion im Tumorboard
- Patientenbezogene Selektionskriterien:  
AZ, Ablehnung, Metastasierung
- Sicherer Sphinkterverlust (Funktion)
- Prospektive Beobachtung, Studien

# Danke für Ihre Aufmerksamkeit



**EHSI** 2017  
VIENNA

**EUROPEAN HERNIA SOCIETY**

**39<sup>th</sup> Annual International Congress**

Chairman: René H. Fortelny

May 24<sup>th</sup> - 27<sup>th</sup>, 2017

Vienna, Austria

**SAVE THE DATE**



[www.ehs2017vienna.com](http://www.ehs2017vienna.com)